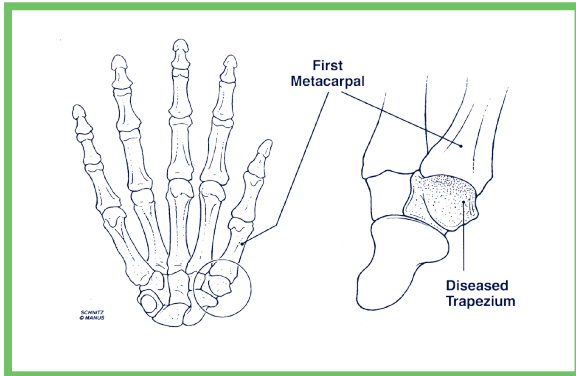


## WHAT IS ARTHRITIS AT THE BASE OF THE THUMB?

Any condition that irritates or destroys a joint is referred to as arthritis. The most common form is osteoarthritis, or as it is sometimes known, degenerative joint disease. In a normal joint, cartilage covers the ends of articulating bones and permits their smooth, painless movement against one another. In osteoarthritis, the cartilage layer wears out, permitting bone to make contact against bone. As this process proceeds to destroy the joint, the signs and symptoms of arthritis develop.



### *Basilar Joint: joint at the base of the thumb*

The basilar joint, or the first carpometacarpal joint of the thumb, is formed by a small wrist bone called the trapezium and the thumb metacarpal bone. The unique shapes of these bones permit the thumb to move in and out of the plane of the palm, as well as bend across the palm to oppose the other fingers. Arthritis involving the base of the thumb is far more common in women than in men, and typically occurs after the age of 40. A prior history of fracture or other injury to the joint may increase the likelihood of developing arthritis.

## WHAT ARE THE SYMPTOMS?

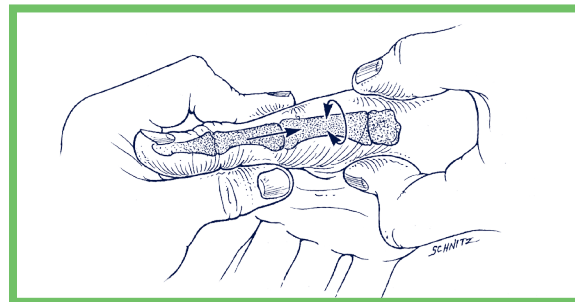
The earliest symptom of basilar joint arthritis

is pain with activities that involve pinch. These include opening jars, doorknobs, car doors and turning keys. Prolonged or heavy use of the thumb may produce an aching discomfort at the base of the thumb. Changes in the weather may produce similar symptoms. As the disease progresses, less stress is required to produce the pain. Pinch strength diminishes. Activity-related swelling may develop. Later, any motion of the thumb, even without stress, may become painful. Eventually, the joint begins to appear enlarged and out of place. This is usually accompanied by limited thumb motion.

The amount of functional loss to the thumb may vary as the disease progresses. Early on, motion of the thumb is normal. Later, however, motion becomes impaired. Often, the most difficult maneuver is pulling the thumb away from the hand, as needed to reach around an object. In severe cases, the thumb metacarpal collapses into the palm and other joints may assume an abnormal position to permit a wider grasp.

## HOW IS THE DIAGNOSIS MADE?

A careful history will frequently alert the physician to suspect basilar joint arthritis. Inspection of the thumb will sometimes reveal a tender prominence at the base of the thumb that represents either inflammation of the joint or displacement of the thumb metacarpal.



### *Assessment performed by your physician*

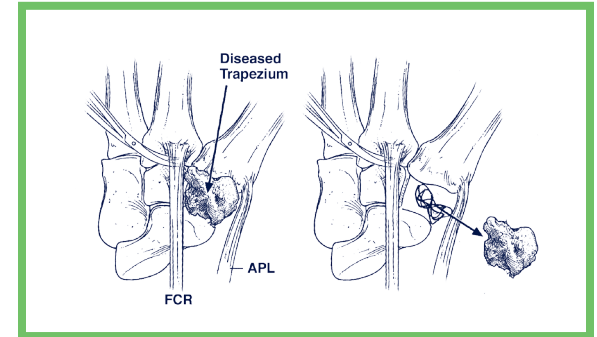
As a diagnostic measure, your physician may press the thumb metacarpal firmly against the trapezium and move the joint.

This grind test will usually reproduce the symptoms of pain, and may produce a gritty sensation called crepitus. This represents bone contact against bone, which also may show up on an x-ray.

## HOW IS IT TREATED?

Initially, the symptoms of basilar joint arthritis will respond to limited activities and rest. If this fails, use of an anti-inflammatory medication and a protective splint may be of benefit. Additional relief of symptoms can sometimes be achieved by a cortisone injection of the joint. When conservative methods of treatment no longer provide benefit, surgery may be warranted.

The goal of surgery is to decrease pain and preserve motion in the thumb. This is accomplished by removing the destroyed joint and creating a substitute joint called an arthroplasty.



### *The diseased trapezium is removed to prepare the joint for reconstruction*

Presently, two types of procedures are used to reconstruct the joint. Both involve removing all, or part, of the trapezium and replacing it with either an artificial substance or a strip of tendon to create a sling suspension. These procedures can be

performed on an outpatient basis and require either a regional block or general anesthetic. A small, stainless steel pin may be used to temporarily stabilize the reconstructed joint.

Following surgery, the hand is immobilized in a bulky compressive dressing with a rigid splint to protect the thumb. The fingers are usually left free to permit early motion. Motion may be permitted at the tip of the thumb. Elevation of the entire upper extremity and movement of the fingers is extremely important to prevent undesired swelling. Although the fingers and tip of the thumb are free, the hand is generally not able to do normal daily activities in the bulky dressing. The postoperative dressing is changed and sutures are removed 10 to 14 days after surgery. A wrist and thumb splint or cast will next be applied for an additional two to four weeks of immobilization. Approximately four to six weeks following surgery, a therapy program is initiated for restoring motion to the thumb. The fixation pin, if not previously removed, is removed at this time. A small splint is made to protect the thumb between exercises and to maintain the web space between the thumb and index finger.

A therapist will provide a specific exercise program and advice on what activities are allowed. Discomfort with the early therapy is not uncommon and improves with time. If necessary, additional appointments will be made with the hand therapist for periodic checks on the progress of therapy. Unrestricted use of the thumb is usually permissible at 12 weeks after surgery. Up to one year may be required before the maximum benefits of surgery are achieved.

## ARTHRITIS AT THE BASE OF THE THUMB



**The Louisiana Hand  
and Elbow Center**

T (985) 625-2200

F (985) 625-2206

604 North Acadia Road, Suite 508  
Thibodaux, LA 70301



**The Louisiana Hand  
and Elbow Center**